

**PATIENT**

Suki Miklochik

SPECIES

Feline

BREED

DSH

SEX

Female Spayed

AGE

4.1.09

WEIGHT

10.6lbs

INTERPRETED BYMaggie Machen Lamy,
DVM, DACVIM
(Cardiology)**HOSPITAL NAME**Northwind Animal
Hospital**REFERRING VET**

Dr. Cross

INVOICE

23639

DATE

4.13.22

PRESENTING CLINICAL SIGNS

History: Diagnosed with grade 2/6 murmur. Assess prior to dental.

-Current medications: None.

-Sedation used: Not required to complete full diagnostic ultrasound.

-Pertinent previous ultrasound results: No previous.

-STAT: Not requested

-Imaging performed by: Stephanie Pearce RDCS, RVT.

RADIOGRAPHIC FINDINGS *NOTE: Images submitted for supplemental information only.

Normal cardiac silhouette. No obvious evidence of CHF.

ECHOCARDIOGRAM FINDINGS

2D, m-mode, color flow and doppler imaging is available. The left ventricular wall thickness is low normal yet highly remodeled with regions of irregularity. There is a diffusely hyperechoic endocardium consistent with fibrosis and ventricular remodeling. The left ventricular chamber is normal in dimension. The papillary muscles appear remodeled as well. The left atrium is normal in size. The right atrium is normal. Mild tricuspid regurgitation identified. The right ventricle appears normal. The mitral valve is normal in structure and mobility. There is no mitral regurgitation present. Blood flow through both the LVOT and RVOT are normal in velocity. No effusions or cardiac tumors are evident.

CARDIAC CHART

FELINE CARDIAC PARAMETERS	BODY WEIGHT (kg)	HR (BPM)	IVSd (cm) <small>(Moise, Pipers)</small>	LVIDd (cm) <small>(Moise, Pipers)</small>	LWVd (cm) <small>(Moise, Pipers)</small>	FS (%)	EF (%)
NORMAL PARAMETER	-----	150-240	3.5-0.55	<2 (mean 1.5)	3.5-0.55	35-67	80-100
PATIENT	4.8	NM	0.53	1.0	0.43	63	94
FELINE CARDIAC PARAMETERS	LA/AO <small>(Boon)</small>	LA/AO HEART BASE (Swe) <small>(Abbott)</small>	LA 2D short axis Base view (cm) <small>(Abbott)</small>	LVOT VEL (m/s)	RVOT VEL (m/s)	E max (m/s)	
NORMAL	<1.5	<1.3	<1.2	<1.6	<1.3	<0.9	
PATIENT	NM	1.2	1.0	1.0	1.1	NM	

Adapted from June Boon, Veterinary Echocardiography, 1998
Abbott J & MacLean H JVIM 2006;20: 111-119, Moise et al. Am J Vet Res 47:1476, 1986. Pipers et al. Am J Vet Res 40:882, 1979.

INTERPRETATION OF THE FINDINGS & FURTHER RECOMMENDATIONS

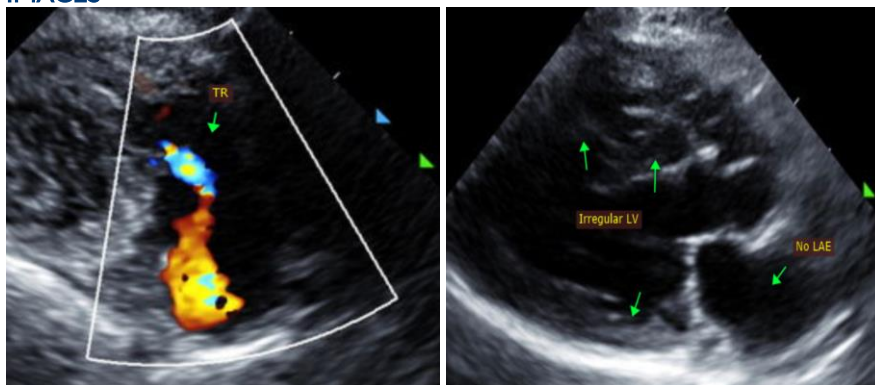
The only cause of the murmur seen here is mild tricuspid regurgitation. TR is most commonly physiologic in origin and of little hemodynamic significance. The right atrium is normal, indication low risk for complication. There is also a significant amount of remodeling and fibrosis of the left ventricular wall, which is likely due to normal aging, however, is of unknown relevance at this juncture. No additional issues are identified.

No medications are indicated at this juncture as there is low risk for complication with minimal atrial dilation. Monitor in the future for respiratory compromise, syncope/lethargy, or signs of a blood clot (paralysis, lameness).

The cardiac risk for general anesthesia is mild, however heart rate stimulating drugs such as atropine, glycopyrrolate or ketamine should be avoided unless medically necessary. Even without significant pathology, with this degree of remodeling and diastolic stiffening there is elevated risk for fluid overload in this patient. Judicious IV fluid use is recommended.

Recommend recheck echocardiogram in 6-12 months to assess for progression, sooner if any clinical signs develop in the interim.

IMAGES



The information and recommendations provided are based on the images presented by the referring veterinarian. No evaluation can be communicated regarding pathology that was not visible in the image/video clips provided.

Thank you for this referral. This report was generated using transcription software, and minor dictation errors may be present. If the clinical or image interpretation does not parallel your findings or if I can be of any further assistance, please contact me.

Maggie Machen Lamy, DVM
Diplomate of the American College of Veterinary Internal Medicine (Cardiology)
info@sonopath.com